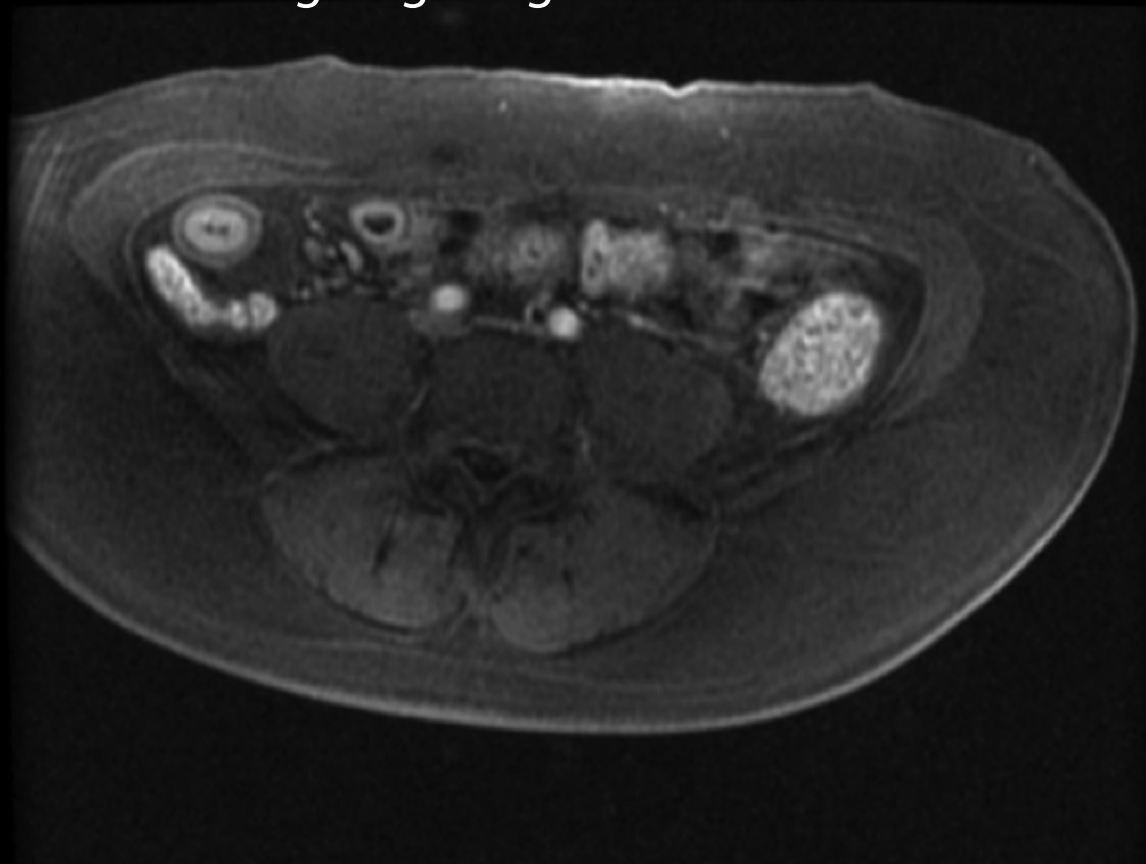


Crohn's disease

Contrast enhanced axial MR scan demonstrating target sign due to mural thickening in terminal ileum



Coronal MR scan (below) showing long segment of terminal and distal ileum with mural thickening and fatty separation

Affected ileum —————

mural thickening —————

